

ISSN 1682-8356
ansinet.org/ijps



INTERNATIONAL JOURNAL OF
POULTRY SCIENCE

ANSI*net*

308 Lasani Town, Sargodha Road, Faisalabad - Pakistan
Mob: +92 300 3008585, Fax: +92 41 8815544
E-mail: editorijps@gmail.com

Outbreak of Coccidiosis in 5-day Old Commercial Broiler Breeder Flock in Zaria, Nigeria

I.W. Musa¹, L. Sa'idu², I.D. Jatau³, J. Adamu⁴, M.O. Otu⁵ and P.A. Abdu¹

¹Department of Veterinary Surgery and Medicine, Ahmadu Bello University, Zaria, Nigeria

²Veterinary Teaching Hospital, Ahmadu Bello University, Zaria, Nigeria

³Department of Veterinary Parasitology and Entomology, A.B.U. Zaria, Nigeria

⁴Department of Veterinary Pathology and Microbiology, A.B.U. Zaria, Nigeria

⁵National Animal Production and Research Institute, Shika, A.B.U. Zaria, Nigeria

Abstract: Field outbreaks of coccidiosis all over the world were commonly reported in chickens over 3-weeks of age. Outbreak of coccidiosis in birds in the first few weeks of life is becoming increasingly important but chickens less than 1-week of age appeared not to be susceptible. This case report describes the clinical signs and gross lesions of coccidiosis as well as its microscopic appearance in a five-day old intensively managed broiler breeder chicks. The outbreak occurred in December, 2009 and was characterized by early onset of an acute disease with high mortality. Other clinical features of the disease were: progressive increase and sudden decline of high chick mortality of up to 50%, ruffled feathers, blood stained whitish to brownish diarrhea, weakness and anorexia. Gross lesions seen were congested carcasses, distended caeca and intestinal segments with blood, mucus and tissue debris; retained yolk sac was also observed in some birds. Whole intestines were submitted to the Protozoology and retained yolk sac to Microbiology Laboratories for investigations. A farm visit revealed very poor housing ventilation and wet litter. Laboratory results confirmed coccidian schizonts and gametocytes from caeca and intestinal scrapings. *Escherichia coli* was isolated from the yolk sac. High hygienic standards must be maintained in hatcheries and poultry houses, damp and warm litter must be avoided and adequate ventilation should always be provided in poultry houses to prevent coccidiosis.

Key words: Outbreak, coccidiosis, 5-day old, broiler-breeder flock

INTRODUCTION

Poultry production is an important component of the Nigeria's livestock sub-sector. It provides employment, income, animal protein for urban and rural dwellers as well as manure for crops (Eduvie, 2002). In Nigeria, small holder poultry farmers that operate various production strategies provide the bulk of poultry meat and eggs for the populace (Eduvie, 2002). Such farmers obtain their day old chicks mainly from hatcheries within the country (Eduvie, 2002). Avian coccidiosis is a major parasitic disease of poultry with a substantial economic impact to the poultry industries in Nigeria and the world (Trees, 1999; David, 2000; Etuk *et al.*, 2004). Chickens are highly susceptible to about 11 different species of this single celled obligate intracellular parasite of almost exclusively the genus *Eimeria* (Davis, 1981; Adene and Oluleye, 2004; Alberta, 2007). This different pathogenic species of *Eimeria* exhibit different tissue and organ specificity and pathogenicity in poultry (David, 2000; Adene and Oluleye, 2004). Epidemiological studies on coccidiosis in Nigeria indicated 12% prevalence and

contributed up to 37% of all internal parasites of poultry in Ibadan (Adene and Oluleye, 2004). In Zaria, studies indicated *E. tenella* and *E. necatrix* to be the most pathogenic *Eimeria* species causing bloody caecal and intestinal coccidiosis respectively (Bishu, 1982). Coccidiosis is a disease common in intensively managed farms especially where management or hygienic standards are compromised (Adene and Oluleye, 2004). Damp litter that has high moisture content and warmth of 25-30°C favour oocyst sporulation (David, 2000). Sudden outbreak of coccidiosis had occurred following ingestion of high doses of the sporulated oocyst over a short period of time by nonimmune young (3-8 week-old) birds (Davis, 1981; Unquhart *et al.*, 1996; David, 2000). Birds of any age are susceptible to coccidiosis but most birds get infected in the few weeks of life (Chookyinox *et al.*, 2009). A coccidia free environment is not likely achieved; chicks that become infected may develop acquired immunity or succumb to disease if the balance is in favour of the parasite (Chookyinox *et al.*, 2009). Immunity to

coccidiosis in chickens is *Eimeria* specie-specific (Davis, 1981; Unquhart *et al.*, 1996; David, 2000). Birds that survive severe coccidiosis may never be productive while survivors of one strain of *Eimeria* may become infected with another different strain thereby requiring further treatment (Chookyinox *et al.*, 2009). Field outbreaks of coccidiosis in birds less than 3 weeks of age appear not to be common and in chicks less than one week of age appear not to have been reported. Outbreak of both intestinal and caecal coccidiosis in a flock of 5-day old broiler breeder is hereby reported.

MATERIALS AND METHODS

Case report: History: Five dead and two live five-day old broiler breeder chicks from a flock of 250 birds maintained on deep litter were presented to the Avian Clinic of the Veterinary Teaching Hospital, Ahmadu Bello University, Zaria on the 17th December, 2009 for clinical evaluation. The chief complaint was sudden onset of high mortality 2 days prior to presentation. A total of 125 birds were lost. The birds have been on prophylactic treatment with Amprolium 200® (Amprolium) in feed prior to the onset of the problem. The clinical signs observed were ruffled feathers, blood stained whitish to brownish diarrhea inappetence and depression. A visit to the farm revealed poor standard of hygiene and ventilation. Mortality ceased following medication with Amprocox® (Amprolium and Sulfaquinoxaline) in water for 3-5 days.

Gross lesions: During post mortem examination of the dead birds, the following gross lesions were observed, congested skeletal muscles, distended caecal and intestinal segments with frank blood, mucus and tissue debris. There was sloughing of the intestinal mucosae and retained yolk sacs were seen in some birds.

Laboratory investigations: Whole intestinal segments and retained yolk sacs were aseptically collected and submitted to the Protozoology and Microbiology laboratories respectively for parasite identification. Intestinal scrapings were processed according to standard procedure and stained with Giemsa Stain while the retained yolk sac was cultured by inoculating the sample on MacConkey agar and EMB agar media plates for primary isolation of aerobic bacteria at 37°C for 24-48 h.

Protozoology laboratory findings: Schizonts and gametocytes of *Eimeria* species were seen under the microscope on smears of intestinal scrapings stained with Giemsa stain.

Microbiology laboratory findings: *E. coli* was isolated and confirmed by its characteristic production of greenish metallic sheen on EMB agar.

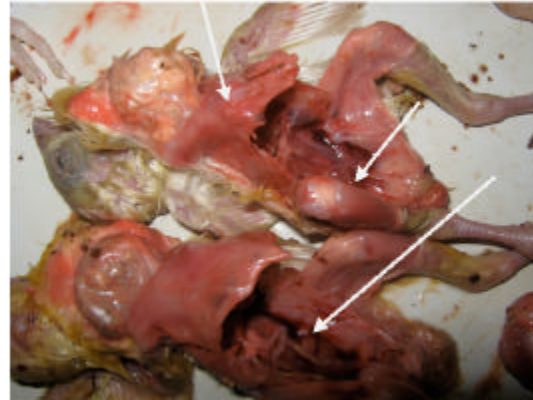


Plate I: Slightly congested skeletal muscles and pale kidneys of coccidian infected 5-day old chicks

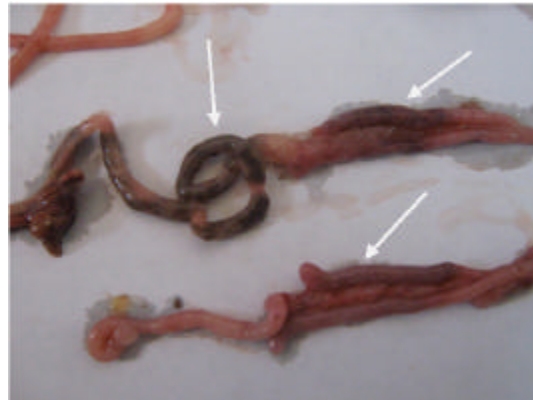


Plate II: Ballooned intestines and caeca of coccidia infected 5-day old chicks

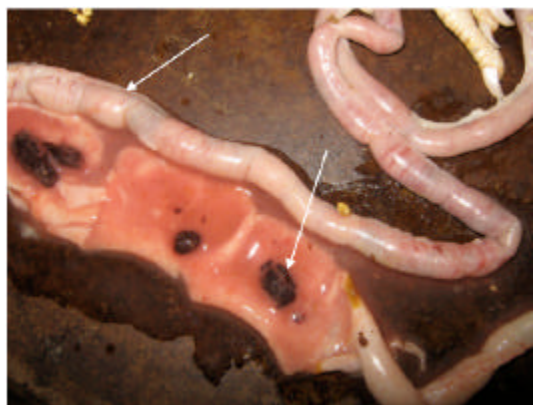

Plate III: Ballooned intestinal segment with blood clot and tissue debris

Diagnosis: Based on the history, clinical signs, gross lesions laboratory investigation the disease was diagnosed as coccidiosis (caecal and intestinal) and colibacillosis.

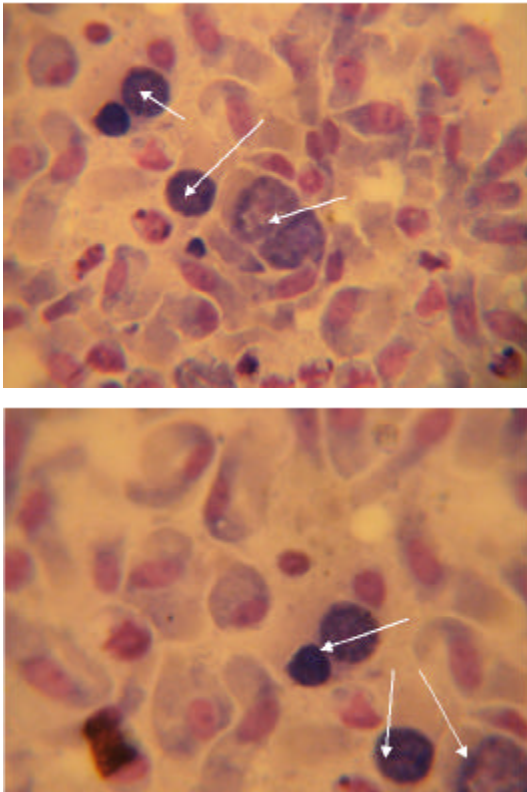


Plate IV: Schizonts and gametocytes (stained with Giemsa) in the intestinal mucosa of 5-day old chicks

RESULTS AND DISCUSSION

Under field situations a tentative diagnosis of coccidiosis can be made based on history, clinical signs, post mortem examination and a minimal parasitological examination (Adene and Oluleye, 2004). The segmental locations and type of the intestinal lesions are highly suggestive of the specie involved in the outbreak. For instance, *E. tenella* parasitizes the caecum while *E. necatrix* is responsible for the mid-intestinal lesions that are associated with the sloughing of the intestinal mucosae (Bishu, 1982; David, 2000; Adene and Oluleye, 2004) as observed in this case. Treatment can therefore be initiated while laboratory investigation confirms the diagnosis (Adene and Oluleye, 2004). Possibilities of intercurrent bacterial infections have been reported (Adene and Oluleye, 2004) as seen in this case where *E. coli* was isolated. Therefore, treatment against secondary bacterial infection in coccidiosis outbreak should often be considered. The timing and nature of this outbreak appeared to be quite unusual. First, December period in the outbreak area usually coincide with cold windy hamatan that is characterized by very low ambient temperature and relative humidity (Abdu *et al.*, 2008). It

has earlier being observed that oocyst sporulation was delayed or not even occur at 10°C in dry conditions, while at 45-50°C oocysts could sporulate within a day, and under optimal conditions of temperature (21-30°C), adequate moisture and oxygen, oocysts could sporulate and become infective within 1-2 days or could get destroyed at 56°C for one hour (Trees, 1999; David, 2000; Etuk *et al.*, 2004). Furthermore, high stocking density was reported to facilitate coccidiosis (Trees, 1999; David, 2000; Etuk *et al.*, 2004). Secondly, there is no existing evidence for now suggesting vertical transmission in coccidiosis that may explain a clinical case of coccidiosis in at least the first week of life as seen in this report. Therefore, the possibility of this flock being exposed at the hatchery because hatchery conditions of 36.9-37.5°C temperature and 60% relative humidity may favour oocyst sporulation and clinical coccidiosis may follow if birds are exposed to sufficient number of the sporulated oocysts. Alternatively, contaminated equipments, feed containers, personnel, rodents, insects and wild birds have been incriminated in the spread of coccidiosis (Abdu *et al.*, 2008; Chookyinox *et al.*, 2009). Any or all of these are good possibilities because cases of coccidiosis have been reported about 3 days following ingestion of large numbers of sporulated oocyst (Unquhart *et al.*, 1996) and under field conditions, the incubation periods for intestinal coccidiosis was reported to be 5 days while that of caecal coccidiosis was 5-6 days (Chookyinox *et al.*, 2009). Furthermore, clinically infected and recovered adult birds have been shown to shed oocysts in their faeces thereby contaminating feed, dust, water and soil (Trees, 1999; David, 2000; Etuk *et al.*, 2004). Furthermore, oocysts have been practically shown to survive outside the host for up to 2 years and resisted low temperatures, dry conditions and many forms of disinfectants (David, 2000). Maternal immunity against coccidiosis was reported to occur at the height of serum antibody production, unfortunately serum antibodies have been found not to be very essential for protection against coccidiosis (Davis, 1981). Prophylactic administration of anticoccidial drugs is a common practice with poultry farmers in Zaria (Abdu *et al.*, 2008). In this farm where this outbreak occurred, amprolium is being used at prophylactic dose in feed. This appears to be in line because coccidiosis is better prevented or treated earlier before irreparable damage is done to the intestine. It has earlier been noted that continuous use of anticoccidial drug might cause therapy to become ineffective due to drug-resistance in parasite population (Debuf, 1994) as observed in this case. Also old or poorly mixed feeds may not be reliable as a preventive approach to coccidiosis and birds must ingest enough of the coocciocides for it to be effective (Chookyinox *et al.*, 2009), these may not be guaranteed in most farms. Enteric pathogens like *E. coli* infection at an early age

like in this case together with this outbreak of coccidiosis may highly suggest poor sanitary and hygienic measures of the farm or hatchery.

Conclusion: Adequate measures must be taken to avoid coccidiosis outbreaks otherwise it will continue to cause considerable losses to the poultry industry particularly when conducive conditions for the parasite development are created. Good sanitary measures, avoiding water spillage, overcrowding and the good use of prophylactic anticoccidia 'shuttle programme' are essential to control the menace of coccidiosis.

REFERENCES

- Abdu, P.A., A.M. Wakawa, N.D.G. Ibrahim and A. Sanusi, 2008. Veterinary Clinical Practice Bulletin. A J. Vet. Teaching Hospital, Ahmadu Bello University, Zaria, Nigeria, 1: 7-13.
- Adene, D.F. and O.B. Oluleye, 2004. Coccidiosis of Poultry: The Biology Diagnosis, Treatment and Control. In: D.F. Adene. Poultry Health and Production Principles and Practices. Stirling-Horden Publishers (Nig.) Ltd. Ibadan, Nigeria, pp: 129-164.
- Alberta, G., 2007. Coccidiosis in chickens. Agriculture and Food. Roping the web. pp: 1-2. <http://www.alberta.chickencoccidiosis.gov.12/25/2008>.
- Bishu, G., 1982. Isolation and identification of two pathogenic *Eimeria* species in chickens in Nigeria. M.Sc. Thesis. Ahmadu Bello University, Zaria, Nigeria, pp: 52-61.
- Chookyinox, L., U. Stella and O. Sandy, 2009. Coccidiosis. Backyard Poultry Information Centre. PhpBB 2004-2009//backyardpoultry.com.
- David, S., 2000. Coccidiosis. Poultry Health and Management. Fourth Edition, ELST with Blackwell Publishers, pp: 105-107.
- Davis, P.J., 1981. Immunity to Coccidiosis. In: Avian Immunology. M.E. Rose, L.N. Pyane and B.M. Freeman (Eds). Poultry Science Symposium No. 16. Clark Constable Ltd. Edingburg, pp: 361-380.
- Debuf, Y., 1994. Bacterial, fungi, viral and protozoal infections. The Veterinary Formulary: Handbook of Medicines used in Veterinary Practice. Second Edition. The Pharmaceutical Press, London, 1: 76-105.
- Etuk, E.B., I.C. Okoli and M.U. Uko, 2004. Prevalence and management issues associated with poultry coccidiosis in Abak agricultural zone of Akwalbom State, Nigeria. Int. J. Poult. Sci., 3: 135-139.
- Eduvie, L.O., 2002. Poultry production in Nigeria, A training Manual. National Animal Production Research Institute. Federal Ministry of Agriculture and Water Resources, Ahmadu Bello University, Zaria, Nigeria.
- Trees, A.J., 1999. Parasitic diseases. In: F.T.W. Jordan and M. Pattison. Poultry Diseases, Fourth edition. W.B. Saunders Company, Ltd., 34: 261-289.
- Unquhart, G.M., J. Armour, J.L. Duncan, J.N. Dunn and F.W. Jennings, 1996. Coccidiosis of Poultry. Blackwell Publishers, London, pp: 228-230.